

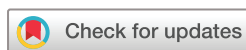Expression of poly(ADP-ribose) polymerase-1 gene and optical coherence tomography angiographic parameters among patients with multiple sclerosis

Elshimaa A Mateen Mossa ,¹ Khulood Muhammad Sayed ,¹ Islam Awany,¹ Nesma A Mohamed,² Tasneem Ali,³ Shimaa Badawy Hemdan,⁴ Ahmed A Helaly,⁵ Mohammed G Abdellatif,⁵ Radwa Mohammed Farag,⁶ Alahmady Hamad Alsmman ,¹ Amr Mounir ¹

To cite: Mossa EAM, Sayed KM, Awany I, *et al.* Expression of poly(ADP-ribose) polymerase-1 gene and optical coherence tomography angiographic parameters among patients with multiple sclerosis. *BMJ Open Ophthalmology* 2022;7:e001157. doi:10.1136/bmjophth-2022-001157

► Additional supplemental material is published online only. To view, please visit the journal online (<http://dx.doi.org/10.1136/bmjophth-2022-001157>).

Received 1 September 2022
Accepted 29 November 2022



© Author(s) (or their employer(s)) 2022. Re-use permitted under CC BY-NC. No commercial re-use. See rights and permissions. Published by BMJ.

For numbered affiliations see end of article.

Correspondence to

Dr Amr Mounir; dramrmonir@yahoo.com

ABSTRACT

Back ground/aims To analyse different parameters of the macula, disc and their vascular affection using optical coherence tomography (OCT) and angiography (OCT-A) in patients with multiple sclerosis (MS) correlating these changes to PARP-1 gene expression in blood.

Methods This cross-sectional study included 80 eyes of the clinically diagnosed relapsing-remitting phenotype of MS. The study included three groups; group (A) included 40 eyes of 20 patients with MS with a history of optic neuritis (MS+ON), group (B) included 40 eyes of 20 patients with MS without a history of ON (MS-ON) and group (C) (the control group) consisted of 40 eyes of 20 matched participants not suffering from any ocular or systemic disease. OCT and OCT-A, RTVue (Optovue, Fremont, California, USA) were done for all eyes for evaluating the macular and disc changes. Qualitative real-time PCR for estimation of PARP1 gene expression level was performed for all patients.

Results PARP-1 gene expression level showed a significant difference in comparing the three groups, with the highest level being for the (ON+) group ($p<0.0009$). Significant negative correlations were found between PARP-1 gene expression level and central macular thickness, total macular volume and full foveal vessel density thickness. ROC curve constructed by plotting the area under the receiver operating characteristic curve value was (0.9) for PARP-1 gene expression level.

Conclusions PARP-1 may play an important role in the development of the ON cascade in patients with MS and may be a biomarker for diagnosing and a potential molecular target of ON in MS patients' therapy. In addition to the OCT and OCT-angio changes that could be detected retrospectively, PARP-1 gene expression level could be considered a prospective detector to complete the full-blown picture of MS (ON+) early and prevent blindness.

INTRODUCTION

Multiple sclerosis (MS) is a disabling disease targeting the central nervous system (CNS) via an autoimmune and inflammatory route. Plaque formation is followed by the

WHAT IS ALREADY KNOWN ON THIS TOPIC

⇒ The most common ocular presentation of multiple sclerosis (MS) is optic neuritis (ON), representing the first clinical manifestation in about 25% of cases.

WHAT THIS STUDY ADDS

⇒ PARP-1 may be a biomarker for diagnosing and a potential molecular target of ON in MS patients' therapy.

HOW THIS STUDY MIGHT AFFECT RESEARCH, PRACTICE OR POLICY

⇒ Qualitative real-time PCR for estimation of PARP1 gene expression level.

destruction of the myelin sheath resulting in axonal degeneration.^{1 2}

The most common ocular presentation of MS is optic neuritis (ON), representing the first clinical manifestation in about 25% of cases.^{3 4} It is confirmed that the visual system is affected through the post-mortem specimens (in the form of axonal loss and degeneration of the optic nerve) in about 94 to 99% of patients with MS whether they had previous ON or not.^{5 6}

Visual pathway in patients with MS represents a directly visible common affected partner of the CNS. In order to objectively quantify and assess the visual pathway, Spectral-domain optical coherence tomography (SD-OCT) is a safe, accurate, non-invasive technique that provides micrometre axial resolution in cross-sectional retinal imaging for reliable quantification of the ganglion cell axonal layer thickness at the level of the peripapillary retinal nerve fibre layer (RNFL) and the macular region.^{7 8}

OCT angiography (OCT-A) is a new, non-invasive imaging technique that produces an angiographic image in a matter of seconds

without using dyes by using motion contrast imaging of high-resolution volumetric blood flow. The en face images of OCT angiograms can be visualised in definite layers starting from the internal limiting membrane down to the choroid, in addition to the visualisation of individual vascular plexus and segmentation of the inner retina, outer retina and choriocapillaris slabs.⁹ Vascular plexus affection of the superficial and deep retinal vessels associated with ON can be the contributor to the neuronal or degenerative dysfunction in patients with MS.¹⁰

Poly (ADP-ribose) polymerase 1 (PARP-1) is one of the well-characterised and most popular members of the PARP nuclear enzyme superfamily, which transfers ADP-ribose units from nicotinamide adenine dinucleotide to a broad panel of acceptor proteins, such as histones and transcription factors. PARP-1 participation was identified in various cellular processes, including DNA repair, proliferation, death signalling of the cells, transcriptional regulation and inflammation. Previous studies on the experimental autoimmune encephalomyelitis model of MS pointed to the importance of PARP-1 in MS pathogenesis, suggesting that the development of PARP-1 inhibitors is a promising approach for MS treatment modulations.¹¹

The study aims to objectively analyse different parameters of the macula and disc using OCT in addition to their vascular affection using OCT-A in patients with MS (with or without ON) vs the normal control group and correlate these changes to PARP-1 gene expression in blood of patients with MS. It may help predict or even prevent the development of ON and subsequent visual disabilities.

MATERIAL AND METHODS

This cross-sectional study included 80 eyes of the clinically diagnosed relapsing-remitting phenotype of MS. The patients were recruited from neurology outpatient

and inpatient clinics from May 2021 to December 2021, Sohag University Hospitals.

The study included three groups; group (A) (MS+ON) had 40 eyes of 20 patients with MS with a history of ON, group (B) (MS-ON) had 40 eyes of 20 patients with MS without a history of ON, and group (C) (control group) consisted of 40 eyes of 20 matched participants not suffering from any ocular or systemic disease.

The study included patients with MS aged 18 years or more diagnosed according to McDonald's criteria 2017.⁷ In groups (A and B), we included only patients at least 3 months after the resolution of the attack. All patients with MS (groups A and B) were on the same line of neurological management.

Patients with media opacity as corneal opacity or dense cataract that interferes with the signal strength of images, patients with any other retinal pathology, such as diabetic retinopathy, retinal degeneration and retinal dystrophies, and those with any other causes of optic neuropathy, including glaucoma, ischaemic and compressive optic neuropathy were excluded. Also, patients with other demyelinating diseases, for example, acute disseminating encephalomyelitis or neuromyelitis optica, were excluded. Patients with acute attacks of ON were excluded, as optic nerve head (ONH) edema would prevent the accurate measurement of RNFL. Eyes with high myopia (more than -6 SD) were rolled out.

The neurological examination was done to determine the type and the severity of MS by using the EDSS Score. The patients underwent a full ophthalmic examination, for example, intraocular pressure assessment (IOP) using the gold-standard applanation tonometry, slit-lamp examination of the anterior segment and retinal assessment by slit-lamp biomicroscopy using a +78 D lens, then OCT and OCT-A, RTVue (Optovue, Fermont, California, USA) were performed for all patients.

Table 1 Sociodemographic and clinical data among the studied group, n=120

Parameter	MS (ON+) N=40		MS (ON-) N=40		Control N=40		*P value
	No	%	No	%	No	%	
Sex							
Females	36	90.0	20	50.0	40	100.0	<0.001
Males	4	10.0	20	50.0	0	0.0	
Side							
OD	20	50.0	20	50.0	20	50.0	1
OS	20	50.0	20	50.0	20	50.0	
Age (years)							
Mean±SD	38±8		34±6		36±5		0.018

*P value was calculated by χ^2 test or one-way ANOVA test wherever suitable.
ANOVA, analysis of variance; MS, multiple sclerosis; ON, optic neuritis.

The technique of OCT of the optic disc

A circular profile of 3.4mm centred on the optic disc manually adjusted to the optic disc margins was taken to assess the peripapillary RNFL thickness. Mean peripapillary RNFL thickness and four quadrants thickness were evaluated. OCT of the macular ganglion cell complex (GCC), including the average and 3mm circular area, was evaluated in the study. OCTA: of ONH was performed using a 4.5×4.5mm scan centred on ONH, and vessel density in the four quadrants was assessed. OCT-A of the macula 6×6mm scan was centred on the fovea in four

levels to determine vascularity at different levels. The full thickness vascular density (internal limiting membrane layer (ILM)-retinal pigment epithelium layer (RPE)) and the superficial vessel density (ILM-IPL) were determined.

Colour code was used in density map images in which the hot colours represented a more flow; hot colours (red and orange) represented functional perfusion areas, while cold colour (blue) represented low perfusion. Total macular volume (TMV), central macular thickness (CMT) and para and perifoveal sectors thickness were evaluated using a 5×5 mm scan centred on the fovea.¹²

Table 2 OCT and OCT-angio parameters

Parameter	MS (ON+) N=40			MS (ON-) N=40			Control N=40			P value*
	Mean	±	SD	Mean	±	SD	Mean	±	SD	
CMT	225	±	18	234	±	21	240	±	18	0.02
TMV	6.53	±	0.39	6.69	±	0.18	6.97	±	0.22	<0.0002
SFVD	15	+	6	24	+	2	19	+	7	<0.004
SS Para-FVD	53	+	4	50	+	4	52	+	3	0.04
SS peri-FVD	49	±	4	49	±	2	51	±	3	0.002
SN para-FVD	51	±	5	52	±	3	49	±	5	0.01
F FVD	227	±	19	239	±	14	245	±	18	0.001
FS Para-FVD	299	±	19	305	±	10	317	±	30	0.005
FS Peri-FVD	262	±	15	273	±	16	279	±	8	<0.0003
FI Para-FVD	296	±	17	298	±	5	320	±	16	<0.0009
FI Peri-FVD	252	±	12	261	±	18	271	±	12	<0.002
FN Para-FVD	302	±	35	298	±	5	312	±	17	0.004
FN Peri-FVD	266	±	22	279	±	18	282	±	15	0.006
FT Para-FVD	290	±	17	289	±	4	309	±	20	<0.001
FT Peri-FVD	250	±	15	258	±	14	272	±	23	<0.009
SRNFL	115	±	15	115	±	17	123	±	9	0.02
IRNFL	111	±	16	111	±	14	127	±	17	<0.002
NRNFL	67	±	9	70	±	12	77	±	11	0.004
TRNFL	62	±	12	56	±	8	73	±	9	<0.0007
Average GCC	85	±	9	85	±	10	97	±	6	<0.002
SGCC	85	±	9	86	±	10	111	±	67	0.02
IGCC	86	±	9	84	±	10	97	±	7	<0.002
SDVD	51	±	5	49	±	2	52	±	5	0.001
IDVD	50	±	8	48	±	4	51	±	5	0.03
NDVD	52	±	6	48	±	4	52	±	6	0.003
TDVD	50	±	5	48	±	4	51	±	5	0.05
BCVA	0.30	±	0.14	0.60	±	0.14	0.89	±	0.12	<0.007

*P value was calculated by one-way ANOVA test.

ANOVA, analysis of variance; Average GCC, average ganglion cell complex thickness; BCVA, best-corrected visual acuity; CMT, central macular thickness; FFVD, full foveal vessel density; FI Para-FVD, full inferior para-FVD; FI-Peri FVD, full inferior peri-FVD; FN Para-FVD, full nasal para FVD; FN Peri-FVD, full nasal peri-FVD; FS Para-FVD, full superior para-FVD; FS Peri-FVD, full superior peri-FVD; FT Para-FVD, full temporal para-FVD; FT Peri-FVD, full temporal peri-FVD; IDVD, inferior disc vessel density; IGCC, inferior GCC thickness; IRNFL, inferior peripapillary retinal nerve fibre layer thickness; MS, multiple sclerosis; NDVD, nasal disc vessel density; NRNFL, nasal peripapillary RNFL thickness; ON, optic neuritis; SDVD, superior disc vessel density; SFVD, superficial FVD; SGCC, superior GCC thickness; SI Para-FVD, superficial inferior para-FVD; SI Peri-FVD, superficial inferior peri-FVD; SN Para-FVD, superficial nasal para-FVD; SRNFL, superior peripapillary RNFL thickness; SS Para-FVD, superficial superior para-FVD; SS Peri-FVD, superficial superior peri-FVD; TDVD, temporal disc vessel density; TMV, total macular volume; TRNFL, temporal peripapillary RNFL thickness.

Cell isolation

The authors isolated mononuclear cells from the peripheral blood collected on EDTA anticoagulant by density gradient centrifugation (Lymphoprep; Axon Lab, Switzerland) Phosphate-buffered saline (PBS) reagent (Biomed, Poland).

The technique of qualitative real-time PCR for the estimation of PARP1 gene expression level.

RNA isolation

RNA was isolated from the samples obtained from peripheral blood mononuclear cells. Isolation of the total cellular mRNA was carried out using GeneJET Whole Blood RNA Purification Mini Kit (Thermo scientific, USA, cat: K0761). Moreover, evaluation of RNA purity (A260/280 ratio of 2.0–2.1) and quantity was done by using the NanoDrop ND-1000 Spectrophotometer (Thermo Fisher Scientific).

Real-time quantitative PCR

Commercially available RevertAid First Strand cDNA Synthesis Kit (Thermo Fisher Scientific, USA cat: K1622) according to the manufacturer's protocol was used for total RNA reverse-transcription. cDNA was employed as a template for (RT-PCR). Real-time PCR on StepOnePlus (Applied Biosystems) using commercially available TaqMan probes (Applied Biosystems, USA) for

endogenous control gene: PUM1 (Hs 00472881_m18); for PARP1 gene: Hs00242302 was used for performing the analysis of PARP-1 gene expression.

The qPCR reaction was carried out in 96-well-optical plates, in the volume of 25 µL/well, consisting of 10.25 µL RNase- and DNase-free ultrapure water, 1.25 µL gene-specific probe, 12.5 µL TaqMan Gene Expression Master Mix ((Inventoried_FAM-MGB) and 1 µL cDNA synthesised in the reverse transcription reaction. The qPCR reaction, after the initial 10 min denaturation at 95°C, was carried out according to the following scheme—40 cycles: 15 s at 95°C and 60 s at 60°C.

Public involvement

Members of the public were involved in different stages of the study including design and conduct. We received input from public continuing online education and implemented them in our study design. We intend to disseminate the main results to participants of the study and will seek public involvement in the development of a suitable method of dissemination.

Statistical analysis

Data were analysed using the SPSS computer program V.25.0. Quantitative data were expressed as mean±SD, median and range. Qualitative data were expressed as numbers and percentages. A χ^2 test or one-way analysis of

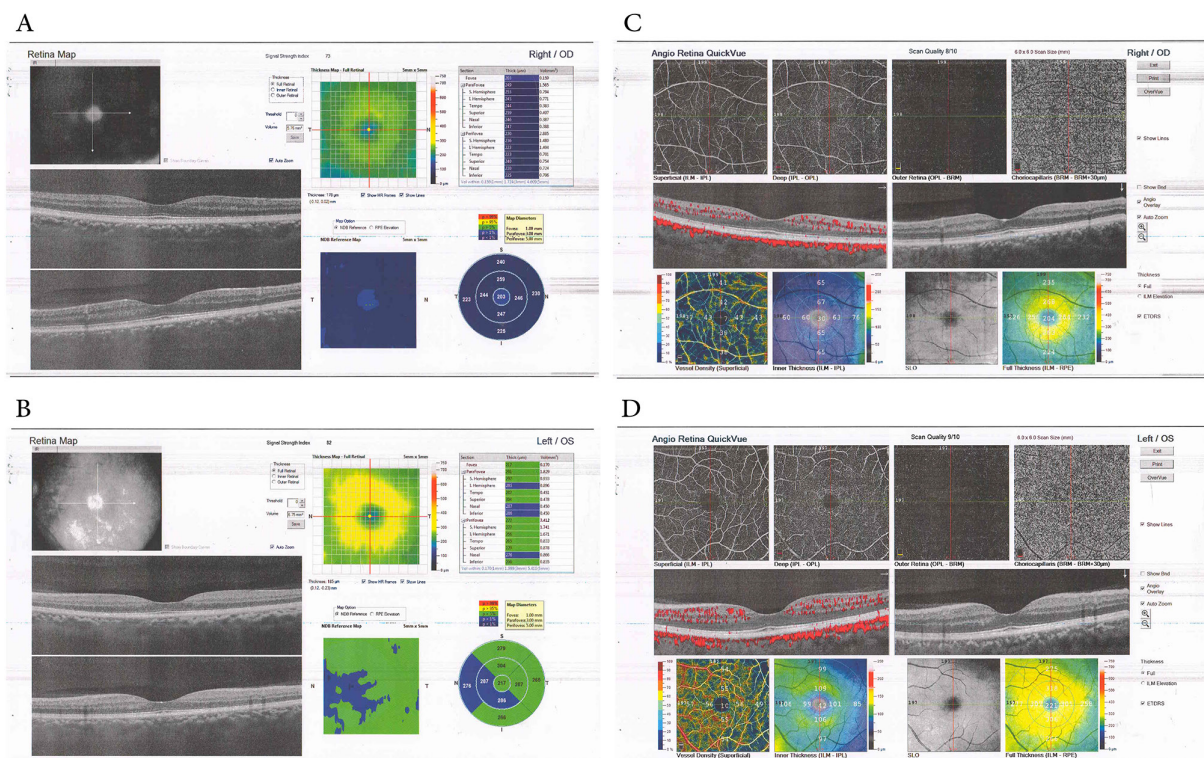


Figure 1 3D OCT macula and OCT-angiography of the macula. (A) Rt.OCT macula of patient with MS (ON+) with marked thinning of central macular thickness and total macular volume. (B) Lt.OCT macula of patient with MS (ON-) with normal central macular thickness and decreased total macular volume. (C) Rt.macula of patient with MS (ON+) showing decreased vessel density in the superficial and full thickness in the foveal, perifoveal and parafoveal sectors. (D) Lt.macula of patient with MS (ON-) with decreased vessel density in the superficial layers and full thickness of the foveal, perifoveal and parafoveal sectors. MS, multiple sclerosis; OCT, coherence tomography angiography; ON, optic neuritis.

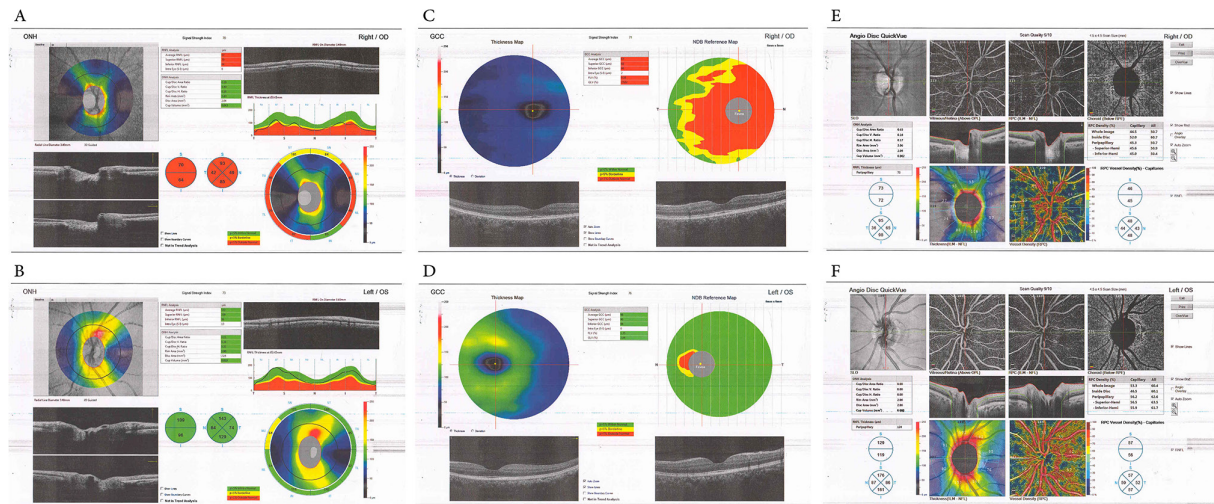


Figure 2 OCT of the optic nerve head, OCT macula-V of ganglion cell complex (GCC) and OCT-angio of the optic nerve head. (A) Rt. disc of patient with MS (ON+) showing marked thinning of the whole sectors of the peripapillary retinal nerve fibre layer. (B) Lt. disc of patient with MS (ON-) showing within the normal thickness of the peripapillary retinal nerve fibre layer. (C) Rt. GCC at the macula of patient with MS (ON+) showing marked thinning of the average, superior and inferior GCC. (D) Lt. GCC at the macula of patient with MS (ON-) showing within the normal thickness of the average, superior and inferior GCC. (E) Rt. Disc of patient with MS (ON+) showing decreased flow (highlighted in blue) with decreased vessel density. (F) Lt. Disc of patient with MS (ON-) showing decreased flow (highlighted in blue) and within normal vessel density. MS, multiple sclerosis; OCT, coherence tomography angiography; ON, optic neuritis.

variance was used to compare the results of the different groups. A 5% level was chosen as a level of significance in all statistical tests used in the study. Post hoc analysis (TUKEY) test was used for further comparison between groups. ROC curve constructed by plotting the area under the receiver operating characteristic curve (AUC).

RESULTS

The study included 120 eyes of 60 subjects; 40 had MS with ON (ON+), 40 had MS without ON (ON-) and 40 were healthy eyes (control group) (table 1).

OCT and OCT-angio parameters were summarised in table 2 and figures 1 and 2.

CMT, TMV, peripapillary RNFL, average GCC, superior GCC, inferior GCC, superficial layers of the foveal vessel density, superior peri and parafoveal sectors of the macular superficial vessel density, full foveal, perifoveal and parafoveal sectors vessel density all were affected with significant thinning affecting MS (ON+) and (ON-) patients compared with the control group. Best-corrected visual acuity (BCVA) was compared between the three studied groups and showed significant reduction among MS (ON+) and MS (ON-) compared with the control group ($p<0.007$). Post hoc test (TUKEY) was done for further comparison between the control group and each of the MS groups (online supplemental table 1).

PARP-1 gene expression level showed a significant difference comparing the three groups with the highest level being for the (ON+) group ($p<0.0009$), as shown in online supplemental table 3.

When the AUC values of the OCT variables were analysed for correct diagnostic power to distinguish between the eyes of healthy control and MS (ON+ and

ON-), none of the parameters had the desired strong diagnostic power (all of AUC <0.5) in ROC curve analysis. The highest AUC value was observed in the CMT (AUC=0.329 (95% CI 0.71 to 0.80), and the second one was the average GCC (AUC=0.183, 95% CI 0.739 to 0.85), while the AUC value of the TMV was determined as 0.166 (95% CI 0.71 to 0.814). In contrast, when (AUC) values of PARP-1 gene expression were analysed for correct diagnostic power to distinguish between healthy control and MS (ON+ and ON-), the highest AUC value was 0.9 (95% CI 0.78 to 0.82). ROC curve analysis and AUC values are shown in figure 3.

Negative correlations were found between PARP-1 gene expression level and CMT ($r=-0.3$, $p=0.001$, TMV ($r=-0.1$, $p=0.05$) and full foveal vessel density thickness ($r=-0.2$, $p=0.004$).

PARP-1 gene expression level was further correlated to both groups of MS (ON+ and ON-) separately, and a significant negative correlations were found between PARP-1 gene expression level and the following parameters in MS (ON+): CMT ($r=-0.465$, $p=0.002$), TMV ($r=-0.420$, $p=0.007$), temporal disc vessel density ($r=-0.428$, $p=0.006$) and BCVA ($r=-0.414$, $p=0.008$) (online supplemental table 2).

DISCUSSION

MS is a well-known, potentially blinding disease that causes multifocal zones of infiltrations by macrophages and T-lymphocytes, which lead to oligodendrocyte death and myelin sheath destruction with the formation of CNS plaques composed of inflammatory cells and their products, demyelinated and transected axons, and astrogliosis affecting both white and grey matter.¹³

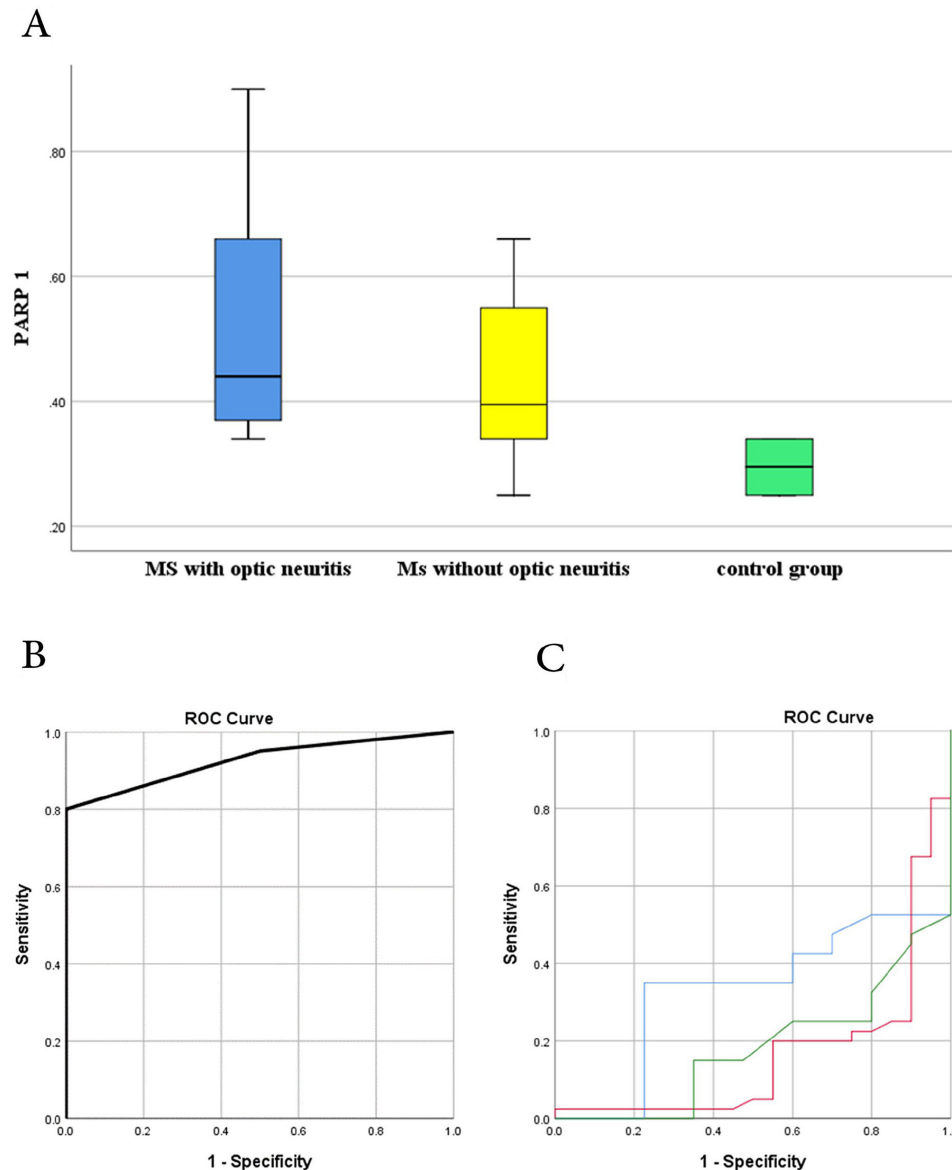


Figure 3 (A) Comparison between the three studied groups (ON+), (ON-) and control group regarding PARP 1 gene expression level. (B) ROC curve constructed by plotting the area under the receiver operating characteristic curve value is (0.9). (C) Rock curve constructed by plotting the area under the receiver operating characteristic curve value is: Blue line: Central macular thickness (0.329). Red line: total macular volume (0.166). Green line: average GCC (0.183). GCC, ganglion cell complex; ON, optic neuritis; ROC, receiver operating characteristic.

There was a significant difference in mean age among the three studied groups (table 1). This is consistent with previous reports that there is a wide range of age at onset (ranges from 15 to 60 years), with typically the most common age of onset (20–40 years).¹⁴

BCVA was compared between the three studied groups and showed significant reduction among MS (ON+) and MS (ON-) compared with the control group (p-value<0.007). It was proved that MS could be associated with poor recovery of BCVA due to neurodegenerative process that may cause dysfunctional mechanisms involving the foveal photoreceptors and bipolar cells.¹⁵

There was significant decrease in (CMT) in groups (A and B) compared with group C, which can be due to the preferential thinning of the central macula relative to the

peripheral macular region in the eyes of patients with MS compared with normal eyes. The histological distribution of the nerve fibre layer and retinal ganglion cell in the macula, could be the cause of this macular thickness pattern. It seems to be particularly informative of neurodegeneration in the eyes of patients with MS whether they have a history of ON or not.¹⁶

We found a significant decrease in the TMV in groups (A and B) when compared with group C, which can be attributed to the analogies between the macular volume and CNS grey matter, as the macula consists of ~34% neuronal cells by average thickness in healthy eyes. Retrograde degeneration from lesions in the optic nerves, chiasm or tracts, could be the origin of the neuronal loss appeared as OCT- macular volume thinning in the eyes

of MS measured by OCT. Those subclinical neurodegeneration findings may be started in eyes with MS even before ON attack, and may be used in the future as a predictive biomarkers of ON attack.¹⁷

There is thinning of the peripapillary (RNFL) thickness in both groups (ON+ and ON-) when compared with the healthy control group, which was consistent with Birkeldh *et al.*¹⁸

Average (GCC), superior (GCC) and inferior (GCC) were found to be thin when compared with the control group, which was also stated by Özbilen *et al.*¹⁹

OCT-A is considered a reliable marker of disease and disability in definite patients with MS.²⁰

We found a marked thinning of the superficial and full macular capillary plexus thickness in both groups (ON+and ON-) compared with the control group. This finding is consistent with Rogaczewska *et al.*, who stated that the superficial capillary plexus thickness was significantly lower in the eyes of patients with MS than in the controls.²¹

Peripapillary region vessel density reduction in the whole sectors, revealed through OCT-angio, is consistent with Feucht *et al.*, who considered such reduction of blood supply correlated to tissue atrophy with subsequent reduction of their metabolic needs.¹⁰

However, our finding of vessel density reduction in both macula and peripapillary capillary plexus is consistent with Cennamo *et al* that the RNFL might suffer indirectly from vascular damage to the optic nerve, and the story might start as a vasculopathy ended by nerve fibre layer reduction.²²

When the AUC values of the OCT variables was analysed for correct diagnostic power to distinguish the eyes of healthy control and definite MS (ON+ and ON-), the highest AUC value was observed in the CMT (AUC=0.329 (95% CI 0.71 to 0.80), and the second one was the average GCC (AUC=0.183, 95% CI 0.739 to 0.85), while the AUC value of the TMV was determined as 0.166 (95% CI 0.71 to 0.814). This finding was consistent with Lamirel *et al* and M. and Poplyak *et al.*^{23 24}

However, none of the above-mentioned parameters had the desired strong diagnostic power (all of AUC<0.5) in ROC curve analysis. This finding was consistent with Özbilen *et al.*¹⁹ however, this could also be attributed to the small sample size of the study.

PARP1 gene expression level was found higher in (MS ON+) compared with (MS ON-) and control groups. To further evaluate the diagnostic significance of PARP-1, the ROC curve was constructed by plotting the AUC value (AUC 0.9, 95% CI 0.78 to 0.82). In a study performed on peripheral blood monocytes of relapsing-remission patients with MS and secondary progressive MS (SPMS), Farez *et al* showed that PARP-1 enzymatic activity was significantly higher in patients with SPMS.²⁵

The above-mentioned variables highlight the correct diagnostic power distinguishing patients with MS from a healthy control. We found that the OCT parameters are biomarkers of definite patients with MS who had previous

attacks. They may be replaced by a more powerful and conclusive biomarker that may be even detected prior to opthalmic damage, the PARP-1 gene expression level.

We found a higher expression of PARP-1 patients with MS with ON compared with patients without ON and control groups. Luo *et al.*²⁶ suggested that PARP-1 negatively regulates the immunosuppressive function of Treg cells at the post-translational level by way of FOXP3 poly (ADP-ribosyl)ation. Collectively, these data suggest a potentially important impact of the deregulation of the PARP-1/TGFBR axis on T-cell function in MS.²⁷

We found a significant negative correlation between PARP1 gene expression level and CMT, TMV and full-thickness foveal vessel density in both groups of MS (ON+and ON-). PARP-1 gene expression level was further correlated to both groups of (MS ON+) and (MS ON-) and a significant negative correlations were found between PARP-1 gene expression level and the following parameters in MS (ON+): CMT ($r=-0.465$, $p=0.002$), TMV ($r=-0.420$, $p=0.007$), Temporal disc vessel density($r=-0.428$, $p=0.006$) and BCVA($r=-0.414$, $p=0.008$). To the best of our knowledge, this is the first time to correlate PARP1 gene expression level to macular OCT and OCT-angio parameters.

It was proved that (PARP1) has a role in neurodegenerative diseases. PARP1 links to a cluster of stress signals arrived by inflammation, and excessive inflammation predisposes the vasculature to stiffening, dysfunction and alteration of endothelial function which will lead to chronic inflammation and tissue damage, which in case of MS disease neurosis may be the sign of such tissue damage.^{28 29}

Limitations of the study: the small sample size. The evaluated macular area was different among GCC, vessel density at the four different levels, macular volume, full macular thickness and parafoveal and perifoveal sectors thickness.

In conclusion: PARP-1 may play an important role in the development of the ON cascade (excessive inflammation which lead to angiopathy and subsequent tissue damage and neurosis) in patients with MS and may be a biomarker for diagnosing and a potential molecular target of ON in MS patients' therapy. In addition to the OCT and OCT-angio changes that could be detected retrospectively, PARP-1 gene expression level could be considered a prospective detector to complete the full-blown picture of MS (ON+) early and prevent blindness. The diagnostic and prognostic values of PARP-1 and therapeutic applications are worth further investigation.

Author affiliations

¹Department of Ophthalmology, Sohag Faculty of Medicine, Sohag University, Sohag, Egypt

²Microbiology and Immunology, Sohag University Faculty of Medicine, Sohag, Egypt

³Department of Public Health and Community Medicine, Sohag Faculty of Medicine, Sohag University, Sohag, Egypt

⁴Department of Medical Biochemistry, Sohag Faculty of Medicine, Sohag University, Sohag, Egypt

⁵Neurology and Psychological Medicine, Sohag University Faculty of Medicine, Sohag, Egypt

⁶Clinical and Chemical Pathology, Sohag University Faculty of Medicine, Sohag, Egypt

Contributors EAMM: The guarantor of the study, data collection, analysis of results AM: interpretation of results, preparation of manuscript, final approval of manuscript KS, IAA, NAM: data collection, editing of manuscript, final approval of manuscript. TA: analysis and interpretation of results, editing of manuscript, final approval of manuscript. SBH: analysis and interpretation of results, editing of manuscript, final approval of manuscript. AAH, AM: analysis and interpretation of results, editing of manuscript, final approval of manuscript. RMF, AHA: study conception and design, analysis and interpretation of results, editing of manuscript, final approval of manuscript. AM is responsible for the overall manuscript.

Funding The authors have not declared a specific grant for this research from any funding agency in the public, commercial or not-for-profit sectors.

Competing interests None declared.

Patient and public involvement Patients and/or the public were not involved in the design, or conduct, or reporting, or dissemination plans of this research.

Patient consent for publication Consent obtained directly from patient(s).

Ethics approval All procedures performed were according to the ethical standards of the institutional and national research committee with the approval of the Medical Research Ethics Committee in Sohag Faculty of Medicine under IBR number: Soh-Med-21-05-20. Participants gave informed consent to participate in the study before taking part.

Provenance and peer review Not commissioned; externally peer reviewed.

Data availability statement Data are available on reasonable request.

Supplemental material This content has been supplied by the author(s). It has not been vetted by BMJ Publishing Group Limited (BMJ) and may not have been peer-reviewed. Any opinions or recommendations discussed are solely those of the author(s) and are not endorsed by BMJ. BMJ disclaims all liability and responsibility arising from any reliance placed on the content. Where the content includes any translated material, BMJ does not warrant the accuracy and reliability of the translations (including but not limited to local regulations, clinical guidelines, terminology, drug names and drug dosages), and is not responsible for any error and/or omissions arising from translation and adaptation or otherwise.

Open access This is an open access article distributed in accordance with the Creative Commons Attribution Non Commercial (CC BY-NC 4.0) license, which permits others to distribute, remix, adapt, build upon this work non-commercially, and license their derivative works on different terms, provided the original work is properly cited, appropriate credit is given, any changes made indicated, and the use is non-commercial. See: <http://creativecommons.org/licenses/by-nc/4.0/>.

ORCID iDs

Elshimaa A Mateen Mossa <http://orcid.org/0000-0001-6989-7483>

Khulood Muhammad Sayed <http://orcid.org/0000-0002-4087-1666>

Alahmady Hamad Alsmman <http://orcid.org/0000-0001-6436-5576>

Amr Mounir <http://orcid.org/0000-0001-9682-671X>

REFERENCES

- Kutzelnigg A, Lassmann H. Pathology of multiple sclerosis and related inflammatory demyelinating diseases. *Handb Clin Neurol* 2014;122:15–58.
- Yousefipour G, Hashemzahi Z, Yasemi M, et al. Findings of optical coherence tomography of retinal nerve fiber layer in two common types of multiple sclerosis. *Acta Med Iran* 2016;54:382–90.
- Syc SB, Saidha S, Newsome SD, et al. Optical coherence tomography segmentation reveals ganglion cell layer pathology after optic neuritis. *Brain* 2012;135:521–33.
- Cennamo G, Romano MR, Vecchio EC, et al. Anatomical and functional retinal changes in multiple sclerosis. *Eye* 2016;30:456–62.
- IKUTA F, Zimmerman HM. Distribution of plaques in seventy autopsy cases of multiple sclerosis in the United States. *Neurology* 1976;26:26–8.
- Toussaint D, Périer O, Verstaappen A, et al. Clinicopathological study of the visual pathways, eyes, and cerebral hemispheres in 32 cases of disseminated sclerosis. *J Clin Neuroophthalmol* 1983;3:211–20.
- Costello F. Optic neuritis revisited. *Int J MS Care* 2006;8:1–4.
- Pul R, Saadat M, Morbiducci F, et al. Longitudinal time-domain optical coherence study of retinal nerve fiber layer in IFNβ-treated and untreated multiple sclerosis patients. *Exp Ther Med* 2016;12:190–200.
- de Carlo TE, Romano A, Waheed NK, et al. A review of optical coherence tomography angiography (OCTA). *Int J Retina Vitreous* 2015;1:1–15.
- Feucht N, Maier M, Lepennetier G, et al. Optical coherence tomography angiography indicates associations of the retinal vascular network and disease activity in multiple sclerosis. *Mult Scler* 2019;25:224–34.
- Ryu KW, Kim D-S, Kraus WL. New facets in the regulation of gene expression by ADP-ribosylation and poly(ADP-ribose) polymerases. *Chem Rev* 2015;115:2453–81.
- Khader SA, Nawar AE, Ghali AA, et al. Evaluation of optical coherence tomography angiography findings in patients with multiple sclerosis. *Indian J Ophthalmol* 2021;69:1457–63.
- Ghasemi N, Razavi S, Nikzad E. Multiple sclerosis: pathogenesis, symptoms, diagnoses and cell-based therapy. *Cell J* 2017;19:1–10.
- Ashtari F, Shaygannejad V, Farazadegan Z, et al. Does early-onset multiple sclerosis differ from adult-onset form in Iranian people. *J Res Med Sci* 2010;15:94–9.
- Ziccardi L, Barbano L, Boffa L, et al. Functional assessment of outer and middle macular layers in multiple sclerosis. *J Clin Med* 2020;9. doi:10.3390/jcm9113766. [Epub ahead of print: 22 11 2020].
- Gugleta K, Mehling M, Kochkorov A, et al. Pattern of macular thickness changes measured by ocular coherence tomography in patients with multiple sclerosis. *Klin Monatsbl Augenheilkd* 2008;225:408–12.
- Burkholder BM, Osborne B, Loguidice MJ, et al. Macular volume determined by optical coherence tomography as a measure of neuronal loss in multiple sclerosis. *Arch Neurol* 2009;66:1366–72.
- Birkeldh U, Manouchehrinia A, Hietala MA, et al. The temporal retinal nerve fiber layer thickness is the most important optical coherence tomography estimate in multiple sclerosis. *Front Neurol* 2017;8:675.
- Özbilen KT, Gündüz T, Kartal Selva Nur Çukurova, et al. Detailed evaluation of macular ganglion cell complex in patients with multiple sclerosis. *Noro Psikiyatr Ars* 2021;58:176–83.
- Murphy OC, Kwakyi O, Iftikhar M, et al. Alterations in the retinal vasculature occur in multiple sclerosis and exhibit novel correlations with disability and visual function measures. *Mult Scler* 2020;26:815–28.
- Rogaczewska M, Michalak S, Stopa M. Macular vessel density differs in multiple sclerosis and neuromyelitis optica spectrum disorder: an optical coherence tomography angiography study. *PLoS One* 2021;16:e0253417.
- Cennamo G, Carotenuto A, Montorio D, et al. Peripapillary vessel density as early biomarker in multiple sclerosis. *Front Neurol* 2020;11:542.
- Lamirel C, Newman NJ, Bioussé V. Optical coherence tomography (OCT) in optic neuritis and multiple sclerosis. *Rev Neurol* 2010;166:978–86.
- Poplyak MO, Trufanov AG, Temniy AV, et al. Changes in retinal structures as markers of multiple sclerosis progression. *Neurology, Neuropsychiatry, Psychosomatics* 2021;13:55–61.
- Farez MF, Quintana FJ, Gandhi R, et al. Erratum: Corrigendum: toll-like receptor 2 and poly(ADP-ribose) polymerase 1 promote central nervous system neuroinflammation in progressive EAE. *Nat Immunol* 2010;11:97.
- Luo X, Nie J, Wang S, et al. Poly(ADP-ribose)ylation of FOXp3 protein mediated by PARP-1 protein regulates the function of regulatory T cells. *J Biol Chem* 2015;290:28675–82.
- Veto S, Acs P, Bauer J, et al. Inhibiting poly (ADP-ribose) polymerase: a potential therapy against oligodendrocyte death in multiple sclerosis. *Clinical Immunology* 2010;135:S30.
- Mao K, Zhang G. The role of PARP1 in neurodegenerative diseases and aging. *Febs J* 2022;289:2013–24.
- Zanoli L, Briet M, Empaña JP, et al. Vascular consequences of inflammation: a position statement from the ESH working group on vascular structure and function and the artery Society. *J Hypertens* 2020;38:1682–98.